

Case Study: 3M™ Clarity™ Aligners

Bite correction of Class III tendency.

Age: 22 | **Sex:** Male

Case summary

Original malocclusion: Anterior edge-to-edge contact with no posterior occlusion.

Treatment overview: Corrected with the aid of Class III elastics, with buttons on the upper 1st molars and lower cuspids, plus attachments on the upper 2nd molars and lower 1st and 2nd bicuspids.

Number of aligners: 20 (dual arch)

Wear interval: 7-8 days

Treatment time: 25 weeks

IPR: 0.3mm on lower anteriors at start, additional 0.3mm at stage 13 on lower anteriors to remove black triangles.

Case courtesy of:
Hughes Orthodontics
Alexandria, Virginia – USA

Profile at rest (*initial*)



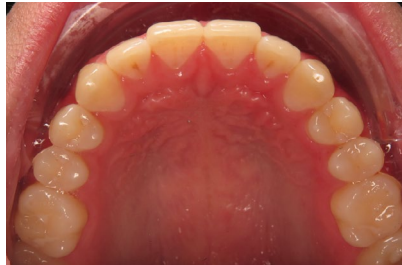Face at rest (*initial*)



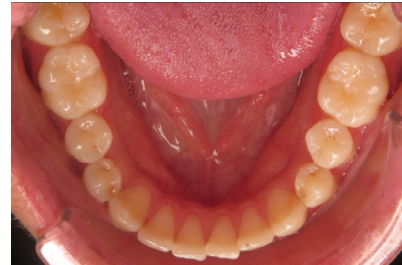
Face smiling (*initial*)



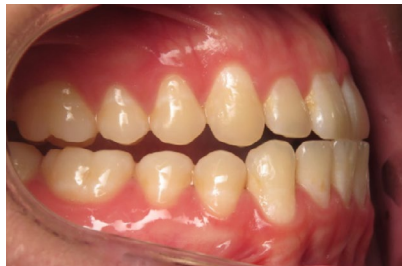Occlusal – Maxillary (*initial*)



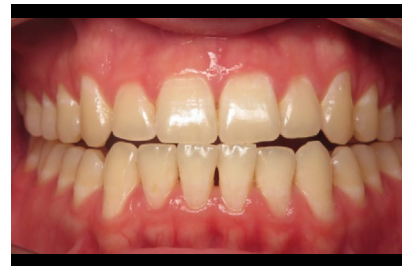Occlusal – Mandibular (*initial*)



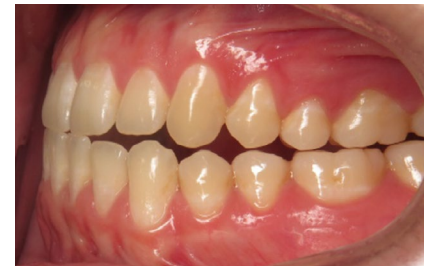Retracted buccal – Right (*initial*)



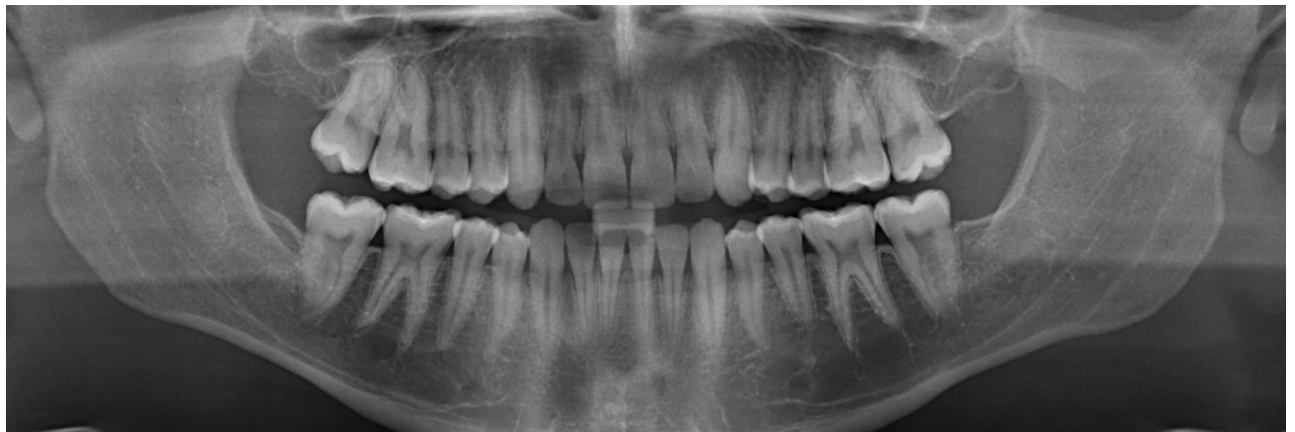Retracted anterior biting (*initial*)

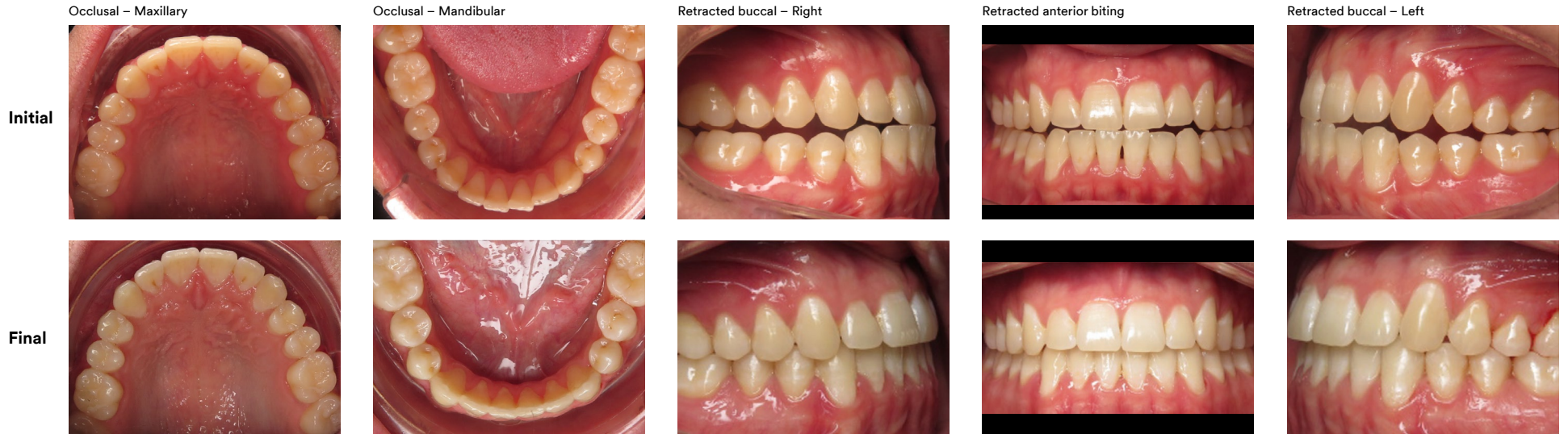

Retracted buccal – Left (*initial*)

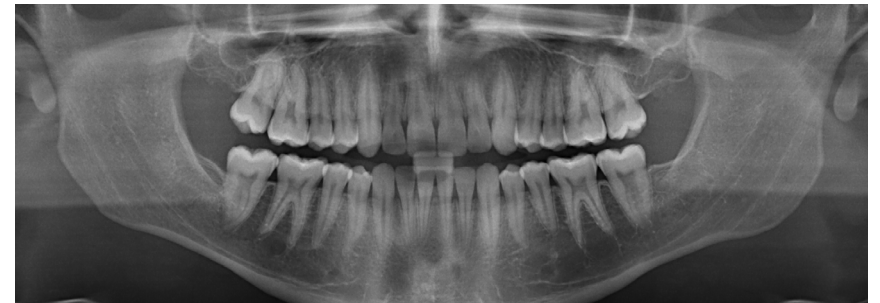

Panoramic radiograph (*initial*)





Initial – Panoramic radiograph



Final – Panoramic radiograph

